Kentucky Equine Research®

TECHNICAL BULLETIN

MFM Pellet™ Case Report

Help comes in the unlikeliest of forms at times. For one dressage horse, relief from a recurring muscle ailment arrived in the form of a scientifically formulated nutritional supplement: MFM Pellet.

An imported seven-year-old Oldenburg gelding training for upper-level dressage was presented periodically for veterinary evaluation over a three-year period for performance-related complaints. These included exercise intolerance, reluctance to engage his hindquarters under saddle, unwillingness to go forward, and behavioral changes when ridden.

On the initial workup, physical examination was within normal limits and, while no lameness was observed, the horse was unable to track up normally while on the longe line. A muscle biopsy revealed mild amylase-sensitive glycogen aggregates consistent with type 2 polysaccharide storage myopathy (PSSM2). At this time, the diet prescribed for PSSM2 was a low-starch, fat-supplemented diet.

Poor performance persisted over the following year, derailing the horse's training. A follow-up veterinary evaluation revealed mild lameness in two limbs, one fore and one hind, but not severe enough to account for his reluctance to engage his hindquarters.

A second muscle biopsy was performed and, with advances in PSSM2 research, a special stain called desmin was performed. This revealed desmin aggregates characteristic of a newly discovered muscle disease called myofibrillar myopathy (MFM). The initial diagnosis of PSSM2 was likely based on the accumulation of glycogen between disorganized myofibrils.

Performance continued to decline over the next year and a half on the low-starch, fat-supplemented diet, and mild muscle atrophy was noted over the topline on an otherwise normal physical examination.

MFM: Muscle cells in disarray



This is a portion of one muscle cell in longitudinal section. The bottom left shows orderly alignment of the contractile proteins (myofibrils). The top shows disordered contractile protein—disarray in the same cell. The dark vertical lines are called Z-discs; this seems to be the central area that is disrupted in horses with MFM. At bottom right the Z-disc is partially broken and wiggly in the top myofibrils. This is called Z-disc streaming.

Continued research into MFM indicated a new dietary approach would be helpful for this gelding. Because MFM involves muscle breakdown and atrophy, the diet for MFM horses should provide high-quality protein with an eye toward supplying specific amino acids. Due to his lack of energy, a small amount of sweet feed was added. In addition to good-quality grass hay, this gelding was supplemented with MFM Pellet, a combination of essential amino acids, including the branched-chain amino acids leucine, isoleucine, and valine as well as lysine, threonine, and methionine. Because leucine stimulates protein synthesis in the muscle after exercise, it is especially important. Cysteine, another amino acid, is a key component of many antioxidants, and horses with MFM might have an increased cysteine requirement.

After supplementation of MFM Pellet for three months, the gelding improved dramatically. Continued supplementation over several more months showed a change in histology and desmin aggregates. The gelding now moves forward off the leg, engages his hindquarters, and is much more comfortable during exercise.

MFM Pellet has been fed to other horses diagnosed with MFM. When fed as recommended with a balanced diet, many horses return to a performance career if the disease is caught at an early stage.

Healthy horse

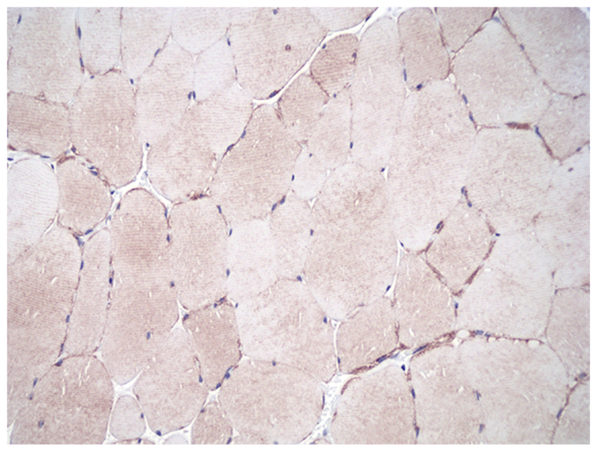

Cross section of muscle cells

MFM-affected horse, September 2017, no supplement

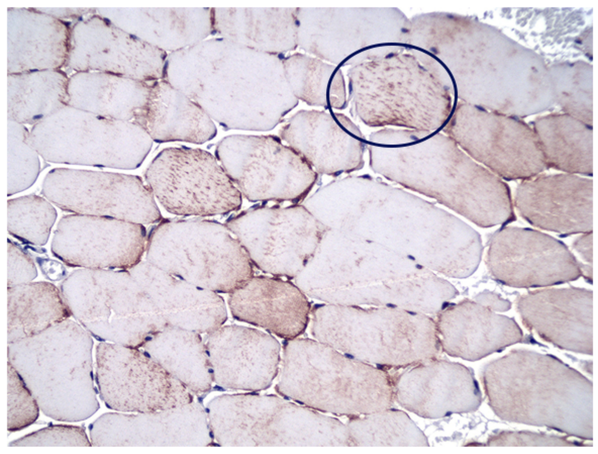

Desmin aggregates

MFM-affected horse, July 2020, supplemented with MFM Pellet